*Review Article*

Journal of Cutaneous Medicine and Surgery
1–7
© The Author(s) 2017
Reprints and permissions:
sagepub.com/journalsPermissions.nav
DOI: 10.1177/1203475417719046
jcms.sagepub.com

Canadian Dermatology Association
Association canadienne de dermatologie

# Amelanotic Lentigo Maligna Melanoma: Mohs Surgery as the Definitive Treatment of an Invisible Tumour

**Marisa Grace Ponzo[1], Richard Ian Crawford[1,2], and Irèn Kossintseva[1]**

**Abstract**

Amelanotic lentigo maligna melanoma represents <2% of melanomas. Diagnosis is delayed owing to the lack of lesion pigmentation and advanced disease at presentation. Excision with appropriate margins is the treatment standard, but the starting point for such margins is often unclear. We describe 2 patients with amelanotic melanoma treated by Mohs micrographic surgery (MMS) that would not have been cleared by wide local excision alone and provide an extensive review of the literature. Both patients presented with histologic diagnoses of malignant melanoma, one with a barely perceptible biopsy site scar on the left infraorbital cheek/lower eyelid (Breslow 1.8 mm) and the second with an amelanotic tumour on the right helix (Breslow 10 mm). Due to location, aggressive histology, amelanotic appearance, and no apparent surrounding skin surface changes, MMS was elected to maximise margin control. For patient 1, invasive and in situ tumour was found at the American Joint Committee on Cancer–recommended margin of 1.5 cm, and the final defect measured 8.5 × 4.8 cm. Patient 2 had a significant invasive and amelanotic lentigo maligna component, resulting in a 9.0 × 6.5-cm defect. MMS allows for immediate histologic feedback on tumour margins of a clinically invisible tumour and thus offers the most definitive treatment.

**Keywords**

amelanotic lentigo maligna melanoma, amelanotic lentigo maligna, Mohs micrographic surgery, surgical margin control, pseudoepitheliomatous hyperplasia

Amelanotic melanoma represents 1.8% to 8.1% of all melanomas, of which amelanotic lentigo maligna melanoma (ALMM) represents an even smaller fraction.[1] Owing to its lack of pigmentation, diagnosis of ALMM is frequently delayed and tends to present with regional and distant metastases.[1] ALMM can masquerade itself as a pruritic erythematous scaly patch or plaque, with a differential diagnosis that includes eczematous dermatitis, actinic keratosis, squamous cell carcinoma in situ, and superficial basal cell carcinoma.[2-8] A paucity of literature discusses the variable presentations and treatment modalities of amelanotic melanoma.

Mohs micrographic surgery (MMS) is a technique that allows for microscopically controlled level-by-level removal of cutaneous malignancies. It offers the highest cure rate for skin cancers and tissue sparing compared with traditional treatment methods.[9] We present a patient with ALMM of the left medial cheek that lacked not only pigment but also any morphological features that could distinguish it from normal skin. A second patient with Fitzpatrick skin type IV presented with amelanotic melanoma on the right helical rim and clinically indistinguishable margins for the lentigo maligna component. We further provide a discussion on the heterogeneous presentations and treatment modalities of ALMM.

## Methods

The institutional research board waived the requirement for ethics review of our retrospective series. Both patients gave written consent for publication of their photographs. MMS was performed in the standard fashion with haematoxylin and eosin (H&E) stains at the Skin Care Centre (University of British Columbia, Vancouver, BC). Immunohistochemical S100 and Melan-A stains were performed on permanent sections. Images from H&E-stained frozen tissue were acquired using the Aperio Slide Scanner and captured with Imagescope software (Leica Biosystems, Buffalo Grove, IL, USA). Amelanosis was defined as a lesion that lacked clinically apparent pigmentation.

[1]Department of Dermatology and Skin Science, University of British Columbia, Vancouver, British Columbia, Canada
[2]Department of Pathology and Laboratory Medicine, University of British Columbia, Vancouver, British Columbia, Canada

**Corresponding Author:**
Marisa G. Ponzo, Department of Dermatology and Skin Science, University of British Columbia, 835 West 10th Avenue, Vancouver, BC V5Z 4E8, Canada.
Email: marisa.ponzo@vch.ca



**Figure 1.** Patient 1: left medial cheek amelanotic lentigo maligna melanoma. Small circular outline denotes the scar from previous biopsy. Large circular outline denotes a 1.5-cm margin as per the American Joint Committee on Cancer (AJCC) guidelines for wide local excision of a melanoma of this Breslow depth (1.8 mm).

A PubMed and EMBASE literature search from 1970 to 2016 was conducted on the heterogeneous presentations and treatment modalities of ALMM and amelanotic lentigo maligna. Pseudoepitheliomatous hyperplasia (PEH), pseudocarcinomatous hyperplasia, and epidermal hyperplasia in conjunction with melanoma were also reviewed in a similar fashion. In addition, broad search terms for amelanotic melanoma, diagnosis, and treatment were used and relevant original articles were extracted and reviewed for data pertaining to lentigo maligna melanoma subtypes.

## Results

### *Patient 1*

An 87-year-old, Fitzpatrick skin type II man presented with a 1-year history of an amelanotic malignant melanoma of a 1.8-mm Breslow thickness, 2 mitoses/mm$^2$, and ulceration (pT2b) on the left infraorbital cheek and lower eyelid. The size of the scar and overlying crust was 1.5 × 0.5 cm (Figure 1). No pigment or surface change was appreciable, and tumour margins could not be delineated by Wood's lamp examination. The patient was otherwise well and had no lymphadenopathy and no hepatosplenomegaly. MMS was indicated because of location, ill-defined borders, size, amelanotic clinical morphology, and aggressive nature of the tumour.

Tumour debulking was performed for frozen histological evaluation. Initial excision markings were made around a 1.5-cm margin (Figure 1), which resulted in a 4.3 × 3.3-cm defect. The tissue was divided into 6 specimens that were mapped, color-coded at the margins, and horizontally sectioned. Invasive amelanotic melanoma (lentigo maligna melanoma subtype) was identified in a portion of the specimens (Figure 2A) as well as a prominent surrounding lentigo maligna component (Figure 2B). Of note, extensive PEH was seen within the invasive melanoma component (Figure 2C). On subsequent Mohs level, siderophages were noted within the conjunctiva (Figure 2D), suggesting distant subconjunctival haemorrhage but not melanoma regression. In total, 6 Mohs levels were required to clear the lesion of microscopic tumour, resulting in the loss of the entire lower eyelid up to the bulbar conjunctiva, the medial canthus, nasal sidewall, and infraorbital, zygomatic, maxillary, and buccal cheek and a corresponding defect measuring 8.5 × 4.8 cm (Figure 2).

The reconstruction was done under general anaesthesia by the plastic surgery service. A left lower eyelid reconstruction with a local flap and chondral graft was performed in addition to a full-thickness skin graft to the left cheek and nose.

### *Patient 2*

The second patient was an 80-year-old man of Fitzpatrick skin type IV who presented for a dermatologist-referred biopsy of a bleeding pink nodule on the right mid-helical rim of 2 months' duration. The tumour was a 2.0 × 1.5-cm exophytic, red, bleeding, friable tumour (Figure 4A). Presence of a blue-white veil on dermoscopy at the base of this otherwise clinically nonpigmented lesion prompted a wedge biopsy that encompassed the entire nodule to establish the correct diagnosis. Permanent pathology revealed invasive superficial spreading melanoma with at least a 10.00-mm Breslow tumour depth, 20 mitoses/mm$^2$, and ulceration (pT4b). Tumour margins were positive for amelanotic lentigo maligna (ALM). A discussion was held regarding therapeutic options, which included (1) wide local excision (WLE) with 2.0-cm margins and no sentinel lymph node biopsy (SLNBx) vs (2) WLE with 2.0-cm margins with SLNBx vs (3) MMS with a minimal starting margin of 1.0 cm (and progressing onwards around the suspicious 4.8 × 3.0-cm faint erythematous patch surrounding the former biopsy scar) and no SLNBx. The patient chose option 3: MMS and no SLNBx. Tumour clearance was achieved after 3 Mohs levels. The final defect post-tumour clearance was 9.0 × 6.5 cm (thereby achieving 2.0-cm margins of clearance) and included an additional post-MMS margin that was sent for permanent pathology evaluation to confirm tumour clearance (Figure 4B). The defect was closed primarily with uncomplicated flaps. Given the high-risk features of this patient's melanoma, he underwent a positron emission tomography (PET) computed tomography (CT), scan which showed no local tissue uptake or regional lymph node involvement but identified multiple lung nodules suspicious for metastatic disease.

## Discussion and Review

Any histological type of cutaneous melanoma can be amelanotic, and ALMM represents an extremely rare subtype.

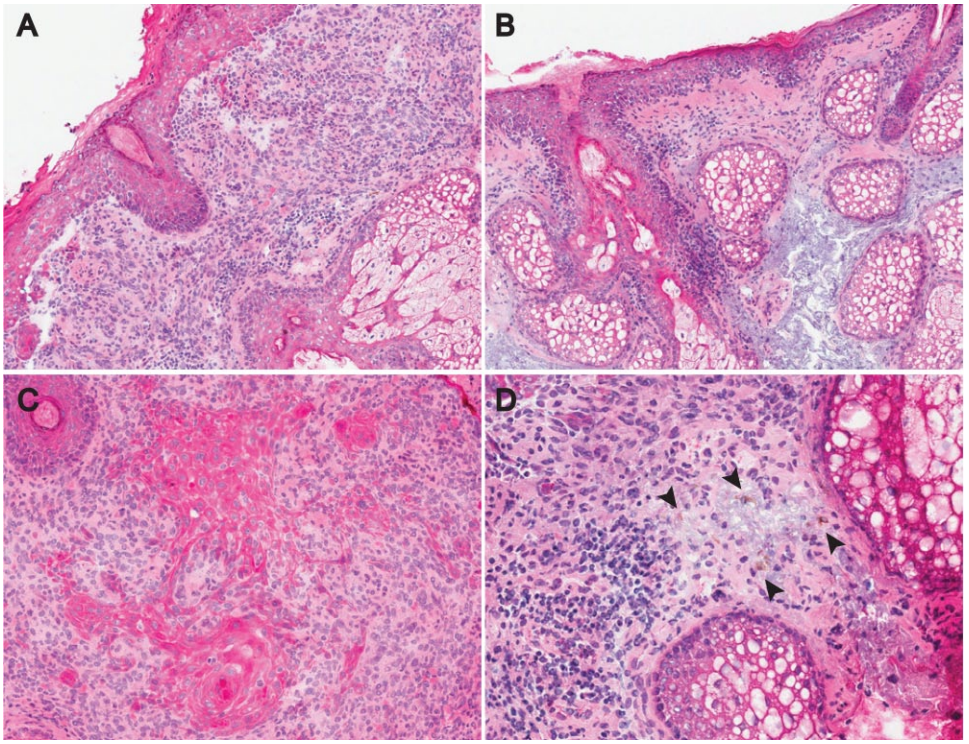


**Figure 2.** Patient 1: histologic features of amelanotic lentigo maligna melanoma on the head and neck demonstrating (A) the invasive component of lentigo maligna melanoma (×10 magnification), (B) lentigo maligna component of the same tumour (×10 magnification), (C) pseudoepitheliomatous hyperplasia within the invasive melanoma component (×20 magnification), and (D) siderophages within the conjunctiva (arrowheads, ×20 magnification). Images were acquired from fresh-frozen tissue sections stained with haematoxylin and eosin.

**Table 1.** Differential Diagnosis of Amelanotic Lentigo Maligna Melanoma.

| |
|---|
| Eczematous dermatitis |
| Dermatophytosis |
| Actinic keratosis |
| Basal cell carcinoma |
| Squamous cell carcinoma in situ |
| Squamous cell carcinoma |

Review of the English-language literature demonstrates that fewer than 50 cases of ALM and ALMM have been reported.[4] These tumours represent a difficult diagnostic challenge for the clinician, and in most cases, lesions were not diagnosed prior to histological examination. The heterogeneous morphological presentation of ALMM, including nonpigmented edematous, erythematous scaly papules or plaques, leads the clinician to suspect a differential diagnosis including eczematous dermatitis, actinic keratosis, basal cell carcinoma, squamous cell carcinoma in situ, and squamous cell carcinoma as opposed to melanoma (Table 1).[2-9]

Due to their bland clinical presentation, amelanotic melanomas tend to be diagnosed later compared to their pigmented counterparts.[10] In a retrospective population-based study of 3467 invasive primary melanomas, of which 275 were histologically amelanotic, amelanotic melanomas were generally of a higher American Joint Committee on Cancer (AJCC) tumour stage at diagnosis compared to pigmented melanomas.[10] Hazard of death from melanoma was higher for amelanotic vs pigmented melanoma. It was postulated by these data and other studies that survival after diagnosis of amelanotic melanoma is poorer than after diagnosis of a pigmented melanoma because of its more advanced stage at presentation. Furthermore, amelanotic melanoma was independently associated with female sex, nodular and unclassified or other histologic subtypes (including lentigo maligna melanoma), increased Breslow thickness, presence of mitoses, severe solar elastosis, and lack of a coexisting nevus (Table 2).[10] Others have suggested similar associations of amelanotic lentigo maligna melanoma with clinical and histological variables (Table 2).[2] Amelanotic melanomas may proliferate and grow faster given the greater number of mitoses and greater Breslow thickness at diagnosis, accounting for their poorer survival rate at diagnosis. Furthermore, ALM has been noted as a precursor lesion to ALMM in some cases.[5,11,12]

Several risk factors may alert the clinician to suspect ALMM. ALMM tends to present in elderly women with an

**Table 2.** Variables Associated With Amelanotic Melanoma and Amelanotic Lentigo Maligna Melanoma.

| |
|---|
| **Clinical variables** |
| Female sex |
| Age >40 years |
| Head and neck location |
| Sun exposure |
| Scaling and pruritus |
| Duration of months to years |
| Standard treatment failure |
| **Histologic variables** |
| Nodular, unclassified, or other histologic subtype |
| Increased Breslow thickness |
| Presence of mitoses |
| Severe solar elastosis |
| Lack of coexisting nevus |

average age of 62 years on chronically sun-exposed sites of the head and neck and rarely other sites such as lower extremities or shoulders.[4,13] Although our 2 exemplary patients were elderly men, their tumours did present on the head and neck region. Lesions are generally reported to have been present for years prior to diagnosis, and some had evolved to ALMM from a previous ALM.[11,14] The clinician should suspect ALMM in patients with longstanding erythematous patches or plaques on chronically sun-exposed skin of the head and neck that have been unresponsive to previous treatments. The clinician should also be suspicious when a trial with empiric treatment for the presumed diagnosis fails and the lesion persists for an extended period of time. For example, if the lesion was felt to be a dermatitis, a course of topical steroids is expected to give some improvement and the clinician should remain suspicious if such a lesion does not improve or resolve. Our recommendations are summarised in the algorithm provided and include performing a biopsy of the suspicious lesion for histological diagnosis as early as possible in the management plan (Figure 5).

PEH is a reactive epithelial proliferation that occurs in response to underlying infectious, inflammatory, and neoplastic conditions and may simulate squamous cell carcinoma. Although reports of PEH within melanocytic nevi are not uncommon, reports of PEH within melanoma are relatively rare.[15-17] There is debate within the literature as to whether the reactive cells are derived from epidermis, follicular, or eccrine epithelium. A recent article studied the tumour microenvironment and the molecular cross-talk between melanoma cells and surrounding keratinocytes using both in vitro and in vivo assays.[18] Melanoma cells co-cultured with human primary keratinocytes secrete growth factors and cytokines (FGF-2, CXCL-1, IL-8, and VEGF-A) that influence the differentiation pattern of surrounding keratinocytes.[18] Previous data are in support of melanoma cells secreting factors that alter the behavior of overlying epidermal keratinocytes.[19] The biological significance of PEH pertains to the tumour microenvironment and may reflect gross tumour behavior and potentially affect staging[20] or response to biologic therapies.

Data comparing the recurrence rates of ALM and ALMM using MMS vs other treatment modalities are not available, but data on lentigo maligna (LM) and lentigo maligna melanoma (LMM) are available and summarised herein (Table 3). Treatment modalities for LM include imiquimod 5% (recurrence rate 0%-20%[21-23]), cryotherapy (recurrence rate 0%-40%[24]), surgical excision (recurrence rate 0%-9.7%[25-27]), MMS (recurrence rate 0%-6.25%[25]), and radiation therapy (recurrence rate 11.5%[22]). Treatment modalities for LMM include surgical excision (recurrence rate 0%-23%[24,28]), MMS (recurrence rate 3%-7%[24,29]), and radiation therapy (recurrence rate 7%-9%[24,30-33]) (Table 3). Of these methods, MMS is the only option that ensures total margin evaluation and may thus incur decreased costs and morbidity for the health care system and patient, respectively. As seen in our retrospective series, the AJCC guidelines for WLE of ALMM tumours would have failed due to the surgeon's inability to fully evaluate the tumour margins, therefore necessitating a series of repeat excisions. The issue is further compounded by the methods of reconstruction when the malignancy is located on cosmetically sensitive areas such as the face where many cosmetic and functional units are within close proximity of each other. If the malignancy is perceived to be cleared, it may be reconstructed with a flap repair; however, should the tumour then be found at the margins, subsequent excisions are much more challenging in terms of ascertaining where the former tumour was. Furthermore, AJCC guidelines for surgical margins for the treatment of primary cutaneous melanoma are controversial for the LM and LMM subtypes of melanoma, and this can be extrapolated to be true for their amelanotic counterparts.[34-36] These subtypes, whether pigmented or not, often present with subclinical atypical junctional hyperplasia in peripheral and periadnexal areas of the lesion, which can extend for several millimeters beyond the visible margins.[34] Controversy surrounds appropriate margin size, whether 5 mm or 9 mm, to achieve local primary tumour control for LM, although the same argument can be extrapolated to LMM as they are thought to exist on a disease spectrum.[37-41]

We and others have proposed that the most cost-effective, tissue-conserving option for patients presenting with ALMM is MMS, as margin control can be assessed at the time of surgery for this clinically invisible tumour.[42,43] A recent study examining the frequency of residual melanoma in WLE specimens after complete excisional biopsy demonstrated that LM and LMM were the most at-risk subtypes.[44] Furthermore, when body location was examined, it was found that the head and neck location was most at risk of having residual melanoma post-WLE.[44] Interestingly, amelanosis was not significantly associated with residual disease. These data make a compelling argument for surgical control of the primary tumour rather than preventing local metastatic disease. MMS is thus an appropriate therapeutic option that not only ascertains clear surgical margins but is also tissue preserving, which is ideal when dealing with tumours that

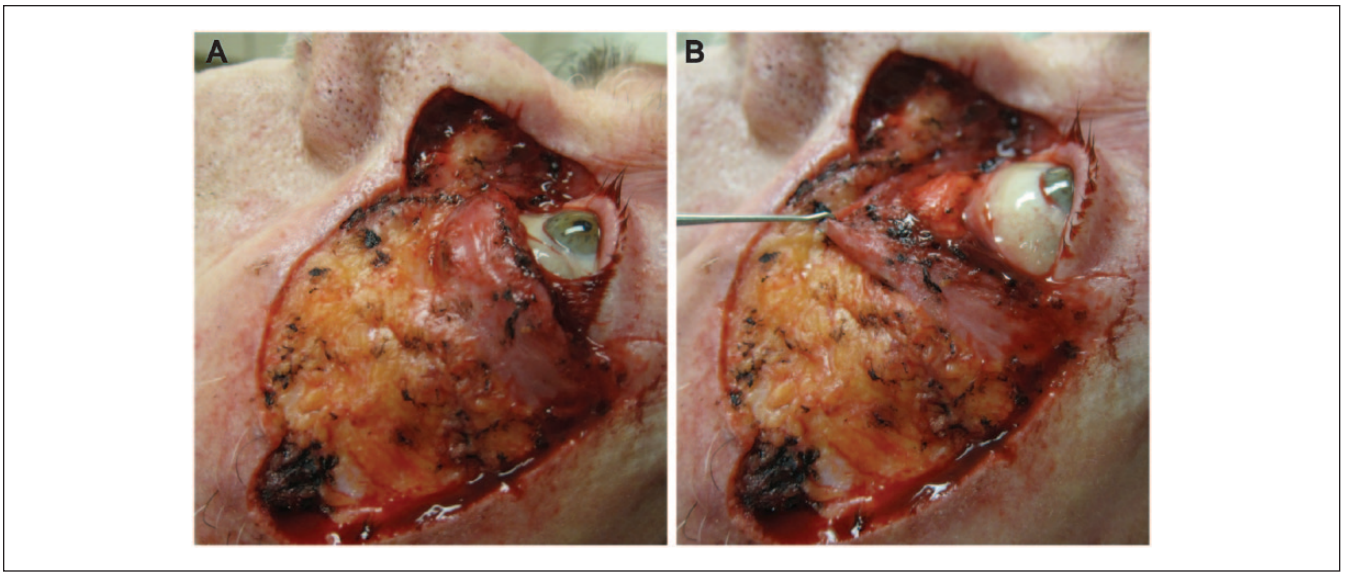


**Figure 3.** Patient 1: defect size following 6 Mohs levels with microscopically clear margins. (A) Loss of the entire lower eyelid up to the bulbar conjunctiva, medial canthus, nasal sidewall, and infraorbital, zygomatic, maxillary, and buccal cheek and a corresponding defect measuring 8.5 × 4.8 cm is shown. (B) Involvement of the bulbar conjunctiva is shown by retraction with skin hook.

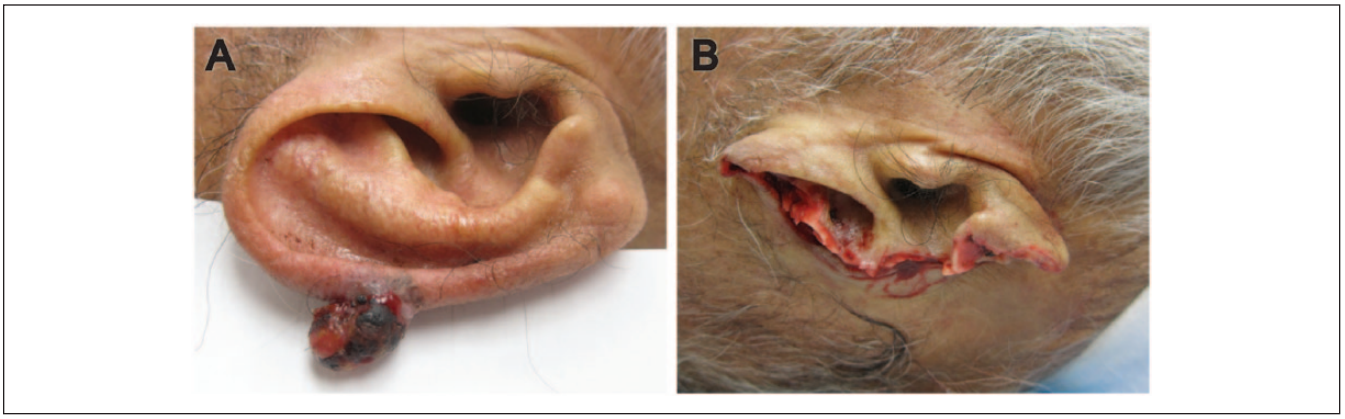


**Figure 4.** Patient 2: Before and after Mohs micrographic surgery treatment. (A) A 2.0 × 1.5-cm exophytic, bleeding friable tumour that demonstrated a blue veil on dermoscopy. (B) The final defect size posttumour clearance was 9.0 × 6.5 cm.

span a large breadth and predominantly occur on cosmetically sensitive areas. MMS also has the added advantage of examining a greater percentage of the histological margin as opposed to a bread-loaf technique used in routine tissue processing, which detects only 19% of positive melanoma margins as reported by Kimyai-Asadi et al.[45]

For patients with ALMM of the head and neck, discussion regarding the utility of SNLBx needs to be considered in the management plan (Figure 5). In general, the usefulness of SNLBx in melanoma remains controversial, as it offers prognostication but no difference in survival outcomes.[46] For melanomas on the head and neck, the issue is further compounded by complex lymphatic drainage patterns and the potential for higher false-negative rates,[47-49] essentially rendering SLNBx futile. In general, patients whose melanomas of the head and neck have an intermediate Breslow thickness (1.2-3.5 mm) or thinner melanomas of less than 1.2 mm with high-risk features (ie, ulceration, high mitotic rate, age younger than 35 years), SNLBx may be offered for prognostic value and regional disease control. However, national guidelines from different countries differ on this point and do not make definitive recommendations.

The limitation of our MMS technique is the lack of immunohistochemistry stains available for frozen-section interpretation. Recent data show added advantage of detecting atypical melanocytes in the LM component of tumours by using S-100 and Melan-A stains as part of the MMS staining technique.[50-54]

Here we report 2 patients with ALMM on the head and neck, one that showed no clinically visible tumour and the other that did present with an amelanotic nodule but whose margins extended far beyond clinical detection. Regarding

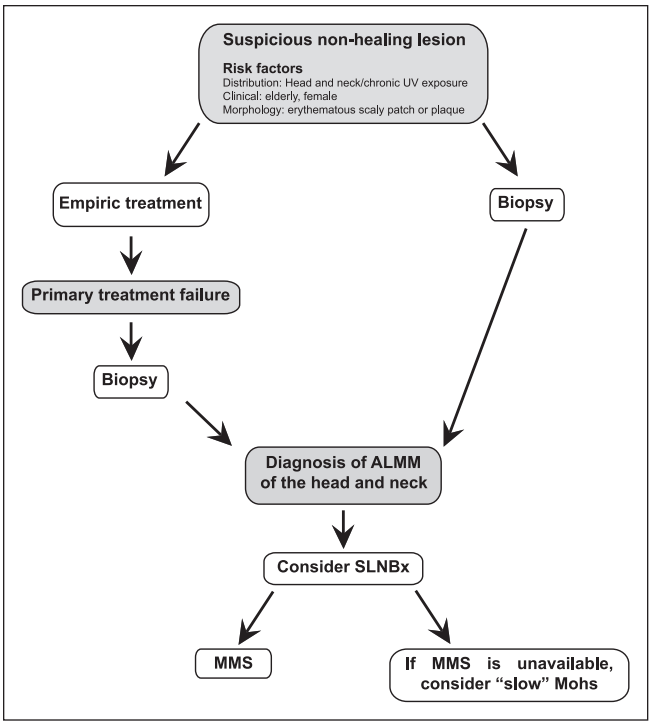


**Figure 5.** Algorithm for the management of a lesion suspicious for amelanotic lentigo maligna melanoma on the head and neck. ALMM, amelanotic lentigo maligna melanoma; MMS, Mohs micrographic surgery; SLNBx, sentinel lymph node biopsy.

**Table 3.** Treatment Modalities and Recurrence Rates of LM and LMM.

| Treatment | Recurrence Rate, % | References |
|---|---|---|
| LM treatment | | |
| MMS | 0-6.25 | 25 |
| Surgical excision | 0-9.7 | 25-27 |
| Radiation therapy | 11.5 | 22 |
| 5% imiquimod | 0-20 | 21-23 |
| Cryotherapy | 0-40 | 24 |
| LMM treatment | | |
| MMS | 3 | 25 |
| Radiation therapy | 7-9 | 24, 30-33 |
| Surgical excision | 0-23 | 24, 28 |

LM, lentigo maligna; LMM, lentigo maligna melanoma; MMS, Mohs micrographic surgery.

the patients discussed, the AJCC guidelines for standard surgical excision margins would have failed, necessitating further surgery and reconstruction. We feel that MMS is both an effective, healthy tissue-preserving and cost-effective method of managing ALMM of the head and neck as well as the surrounding LM tumour component.

## Declaration of Conflicting Interests

The author(s) declared no potential conflicts of interest with respect to the research, authorship, and/or publication of this article.

## Funding

The author(s) received no financial support for the research, authorship, and/or publication of this article.

## References

1. Moreau JF, Weissfeld JL, Ferris LK. Characteristics and survival of patients with invasive amelanotic melanoma in the USA. *Melanoma Res*. 2013;23:408-413.
2. Conrad N, Jackson B, Goldberg L. Amelanotic lentigo maligna melanoma: a unique case presentation. *Dermatol Surg*. 1999;25:408-411.
3. Borkovic SP, Schwartz RA. Amelanotic lentigo maligna melanoma manifesting as a dermatitislike plaque. *Arch Dermatol*. 1983;119:423-425.
4. Abeldaño AM, Saadi ME, Brea P, Kien MC, Chouela E. Amelanotic lentigo maligna melanoma. *Skinmed*. 2004;3:41-44.
5. Allan SJ, Dicker AJ, Tidman MJ, McLaren KM, Hunter JA. Amelanotic lentigo maligna and amelanotic lentigo maligna melanoma: a report of three cases mimicking intraepidermal squamous carcinoma. *J Eur Acad Dermatol Venereol*. 1998;11:78-81.
6. Cliff S, Otter M, Holden CA. Amelanotic lentigo maligna melanoma of the face: a case report and review of the literature. *Clin Exp Dermatol*. 1997;22:177-179.
7. Rahbari H, Nabai H, Mehregan AH, Mehregan DA, Mehregan DR, Lipinski J. Amelanotic lentigo maligna melanoma: a diagnostic conundrum—presentation of four new cases. *Cancer*. 1996;77:2052-2057.
8. Herman KL, Shrager JD. Amelanotic lentigo maligna melanoma: a unique case and review of the literature. *Cutis*. 1989;44:45-48.
9. Koch SE, Lange JR. Amelanotic melanoma: the great masquerader. *J Am Acad Dermatol*. 2000;42:731-734.
10. Thomas NE, Kricker A, Waxweiler WT, et al. Comparison of clinicopathologic features and survival of histopathologically amelanotic and pigmented melanomas: a population-based study. *JAMA Dermatol*. 2014;150:1306-1314.
11. Ara M, Maillo C, Martín R, Grasa MP, Carapeto FJ. Recurrent lentigo maligna as amelanotic lentigo maligna melanoma. *J Eur Acad Dermatol Venereol*. 2002;16:506-510.
12. Higgins HW, Lee KC, Galan A, Leffell DJ. Melanoma in situ: Part I. Epidemiology, screening, and clinical features. *J Am Acad Dermatol*. 2015;73:181-190.
13. Inskip M, Rosendahl C. Extrafacial lentigo maligna melanoma is reported often in Australia, more so at lower latitudes. *Australas J Dermatol*. 2016;57:70-71.
14. McKenna DB, Cooper EJ, Kavanagh GM, Davie RM, McLaren KM, Tidman MJ. Amelanotic malignant melanoma following cryosurgery for atypical lentigo maligna. *Clin Exp Dermatol*. 2000;25:600-604.
15. Hanly AJ, Jorda M, Elgart GW. Cutaneous malignant melanoma associated with extensive pseudoepitheliomatous hyperplasia: report of a case and discussion of the origin of pseudoepitheliomatous hyperplasia. *J Cutan Pathol*. 2000;27:153-156.
16. Reis-Filho JS, Gasparetto EL, Schmitt FC, Fillus-Neto J. Pseudoepitheliomatous hyperplasia in cutaneous malignant melanoma: a rare and misleading feature. *J Cutan Pathol*. 2001;28:496-497.
17. Kamino H, Tam ST, Alvarez L. Malignant melanoma with pseudocarcinomatous hyperplasia—an entity that can simulate squamous

cell carcinoma: a light-microscopic and immunohistochemical study of four cases. *Am J Dermatopathol*. 1990;12:446-451.
18. Kodet O, Lacina L, Krejčí E, et al. Melanoma cells influence the differentiation pattern of human epidermal keratinocytes. *Mol Cancer*. 2015;14:1.
19. McCarty MF, Bielenberg DR, Nilsson MB, et al. Epidermal hyperplasia overlying human melanoma correlates with tumour depth and angiogenesis. *Melanoma Res*. 2003;13:379-387.
20. Bønnelykke-Behrndtz ML, Schmidt H, Christensen IJ, et al. Prognostic stratification of ulcerated melanoma: not only the extent matters. *Am J Clin Pathol*. 2014;142:845-856.
21. Kai AC, Richards T, Coleman A, Mallipeddi R, Barlow R, Craythorne EE. Five-year recurrence rate of lentigo maligna after treatment with imiquimod. *Br J Dermatol*. 2016;174:165-168.
22. Read T, Noonan C, David M, et al. A systematic review of non-surgical treatments for lentigo maligna. *J Eur Acad Dermatol Venereol*. 2016;30:748-753.
23. Gautschi M, Oberholzer PA, Baumgartner M, Gadaldi K, Yawalkar N, Hunger RE. Prognostic markers in lentigo maligna patients treated with imiquimod cream: a long-term follow-up study. *J Am Acad Dermatol*. 2016;74:81-87.e1.
24. McKenna JK, Florell SR, Goldman GD, Bowen GM. Lentigo maligna/lentigo maligna melanoma: current state of diagnosis and treatment. *Dermatol Surg*. 2006;32:493-504.
25. McLeod M, Choudhary S, Giannakakis G, Nouri K. Surgical treatments for lentigo maligna: a review. *Dermatol Surg*. 2011;37:1210-1228.
26. Pitman GH, Kopf AW, Bart RS, Casson PR. Treatment of lentigo maligna and lentigo maligna melanoma. *J Dermatol Surg Oncol*. 1979;5:727-737.
27. Coleman WP, Davis RS, Reed RJ, Krementz ET. Treatment of lentigo maligna and lentigo maligna melanoma. *J Dermatol Surg Oncol*. 1980;6:476-479.
28. MacKenzie Ross AD, Haydu LE, Quinn MJ, et al. The association between excision margins and local recurrence in 11,290 thin (T1) primary cutaneous melanomas: a case-control study. *Ann Surg Oncol*. 2016;23:1082-1089.
29. Cohen LM, McCall MW, Zax RH. Mohs micrographic surgery for lentigo maligna and lentigo maligna melanoma: a follow-up study. *Dermatol Surg*. 1998;24:673-677.
30. Farshad A, Burg G, Panizzon R, Dummer R. A retrospective study of 150 patients with lentigo maligna and lentigo maligna melanoma and the efficacy of radiotherapy using Grenz or soft X-rays. *Br J Dermatol*. 2002;146:1042-1046.
31. Harwood AR. Conventional radiotherapy in the treatment of lentigo maligna and lentigo maligna melanoma. *J Am Acad Dermatol*. 1982;6:310-316.
32. Schmid-Wendtner MH, Brunner B, Konz B, et al. Fractionated radiotherapy of lentigo maligna and lentigo maligna melanoma in 64 patients. *J Am Acad Dermatol*. 2000;43:477-482.
33. Arlette JP, Trotter MJ, Trotter T, Temple CLF. Management of lentigo maligna and lentigo maligna melanoma: seminars in surgical oncology. *J Surg Oncol*. 2004;86:179-186.
34. Castro LGM, Messina MC, Loureiro W, et al. Guidelines of the Brazilian Dermatology Society for diagnosis, treatment and follow up of primary cutaneous melanoma, part I. *An Bras Dermatol*. 2015;90:851-861.
35. Marsden JR, Newton-Bishop JA, Burrows L, et al. Revised U.K. guidelines for the management of cutaneous melanoma 2010. *Br J Dermatol*. 2010;163:238-256.
36. Saiag P, Bosquet L, Guillot B, et al. Management of adult patients with cutaneous melanoma without distant metastasis. 2005 update of the French Standards, Options and Recommendations guidelines. Summary report. *Eur J Dermatol*. 2007;17:325-331.
37. Kunishige JH, Brodland DG, Zitelli JA. Margins for standard excision of melanoma in situ. *J Am Acad Dermatol*. 2013;69:164.
38. Kunishige JH, Brodland DG, Zitelli JA. Surgical margins for melanoma in situ. *J Am Acad Dermatol*. 2012;66:438-444.
39. Kunishige JH, Brodland DG, Zitelli JA. Surgical margins for melanoma in situ: when 5-mm margins are really 9 mm. *J Am Acad Dermatol*. 2015;72:745.
40. Duffy KL, Truong A, Bowen GM, et al. Adequacy of 5-mm surgical excision margins for non-lentiginous melanoma in situ. *J Am Acad Dermatol*. 2014;71:835-838.
41. Grossman D, Duffy KL, Bowen GM. Surgical margins for melanoma in situ. *J Am Acad Dermatol*. 2012;67:1068-1071.
42. Tierney EP, Hanke CW. Cost effectiveness of Mohs micrographic surgery: review of the literature. *J Drugs Dermatol*. 2009;8:914-922.
43. Cook J, Zitelli JA. Mohs micrographic surgery: a cost analysis. *J Am Acad Dermatol*. 1998;39:698-703.
44. Bolshinsky V, Lin MJ, Serpell J, et al. Frequency of residual melanoma in wide local excision (WLE) specimens after complete excisional biopsy. *J Am Acad Dermatol*. 2016;74:102-107.
45. Kimyai-Asadi A, Katz T, Goldberg LH, et al. Margin involvement after the excision of melanoma in situ: the need for complete en face examination of the surgical margins. *Dermatol Surg*. 2007;33:1434-1441.
46. Roy JM, Whitfield RJ, Gill PG. Review of the role of sentinel node biopsy in cutaneous head and neck melanoma. *ANZ J Surg*. 2016;86:348-355.
47. Wells KE, Rapaport DP, Cruse CW, et al. Sentinel lymph node biopsy in melanoma of the head and neck. *Plast Reconstr Surg*. 1997;100:591-594.
48. O'Brien CJ, Uren RF, Thompson JF, et al. Prediction of potential metastatic sites in cutaneous head and neck melanoma using lymphoscintigraphy. *Am J Surg*. 1995;170:461-466.
49. Shpitzer T, Segal K, Schachter J, et al. Sentinel node guided surgery for melanoma in the head and neck region. *Melanoma Res*. 2004;14:283-287.
50. Chang KH, Finn DT, Lee D, Bhawan J, Dallal GE, Rogers GS. Novel 16-minute technique for evaluating melanoma resection margins during Mohs surgery. *J Am Acad Dermatol*. 2011;64:107-112.
51. Kimyai-Asadi A, Ayala GB, Goldberg LH, Vujevich J, Jih MH. The 20-minute rapid MART-1 immunostain for malignant melanoma frozen sections. *Dermatol Surg*. 2008;34:498-500.
52. Kelley LC, Starkus L. Immunohistochemical staining of lentigo maligna during Mohs micrographic surgery using MART-1. *J Am Acad Dermatol*. 2002;46:78-84.
53. Newman J, Beal M, Schram SE, Lee PK. Mohs micrographic surgery for lentigo maligna and lentigo maligna melanoma using Mel-5 immunostaining: an update from the University of Minnesota. *Dermatol Surg*. 2013;39:1794-1799.
54. Glass LF, Raziano RM, Clark GS, et al. Rapid frozen section immunostaining of melanocytes by microphthalmia-associated transcription factor. *Am J Dermatopathol*. 2010;32:319-325.